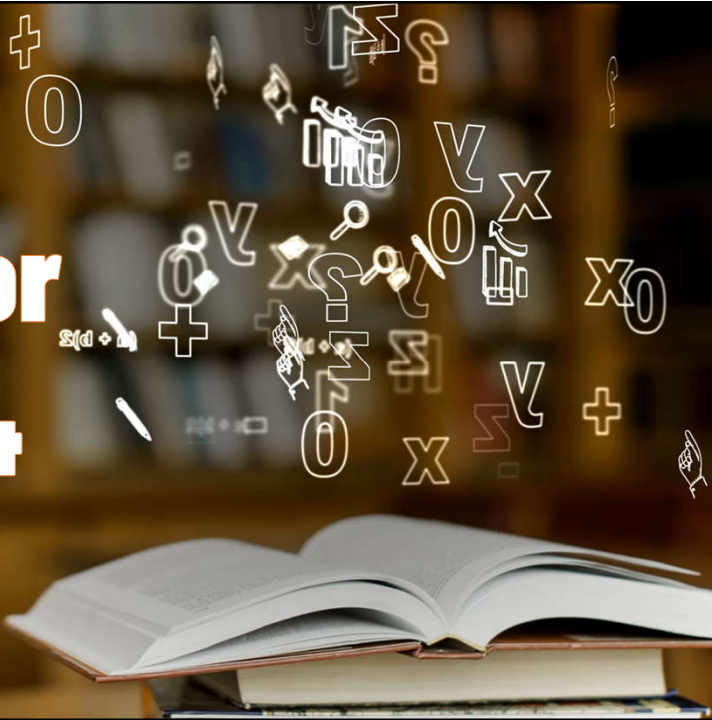




Syllabus For NEET 2024



UPDATED ZOOLOGY CLASS -XI



SN	Chapter Name	Added Portion	Deleted Portion
1	Structural Organization in animals - Animal Tissues	Insect (Frog)	-
2	Digestion and Absorption	-	Deleted
3	Breathing and Exchange of Gases	-	-
4	Body Fluids and Circulation	-	-
5	Excretory Products and their Elimination	-	-

Source - <https://www.nmc.org.in/neet/neet-ug/>

SN	Chapter Name	Added Portion	Deleted Portion
6	Locomotion and Movement	Dealt with Relevant Practical Syllabus	-
7	Neural Control and Coordination	-	Reflex Action & Reflex Arc Sensory Reception
8	Chemical Coordination and Integration	-	-
9	Animal Kingdom (General Account & Non-Chordates)	-	-
10	Animal Kingdom (General Account & Chordates)	-	-

Source - <https://www.nmc.org.in/neet/neet-ug/>

Exercise 33

Aim: To study the human skeleton

Principle: Human skeleton in adults is composed of 206 bones. It is divisible into two categories: Axial and appendicular skeleton. The axial skeleton consists of the bones of the skull, vertebral column, sternum and ribs. The appendicular skeleton consists of the bones of the limbs along with their girdles.

Requirement: Specimens of human skeleton

Procedure

- Observe the different types of bones and joints present in a human skeleton.
- Draw labeled diagram of your observations.

Observation

(a) Human Skull

- It is composed of two sets of bones - cranial and facial (Fig. 33.1).
- Cranial bones are occipital, parietal, frontal, temporal, sphenoid and ethmoid bones.
- Corresponding to their location in the body, the cranial bones have strong bone case for eyes called orbit.
- Facial bones form the front part (i.e., face) of the skull.
- A single U-shaped bone called hyoid is present at the base of the buccal cavity.
- A nasal passage formed by nasal bones is present just below the orbit.
- Maxilla and pre-maxilla bones form the upper jaw, and the mandible bone forms the lower jaw. These two bones also form the face, and into them are lodged teeth in special sockets. Teeth are not bones.
- Distinct sutures in zig-zag fashion are present at the junctions of the frontal with the two parietals, as well as between the two parietals.

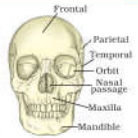

Fig. 33.1 Human Skull

Exercise 33

- The occipital bone has a very big foramen at its posterior base, the foramen magnum, through which the brain is continued posteriorly as a spinal cord.
- The skull is dicondylic, i.e., it has two occipital condyles for articulation with the first cervical vertebra.

Note: The cranium forms the hard protective outer covering for the brain. All the bones of the cranium are articulated by fibrous or fixed or immovable joints. Mandible is the strongest bone of the body.

(b) Vertebral Column

- It consists of 26 serially arranged units (Fig. 33.2) called vertebrae (singular: vertebra).
- Each vertebra has a central hollow portion called neural canal through which the spinal cord passes. The first vertebra is the atlas and it articulates with the occipital condyles of skull.
- Vertebral column has several types of vertebrae: cervical (7), thoracic (12), lumbar (5), sacral (1 which is fused), and caudal or coccygeal (1 which is fused).
- A typical vertebra (Fig. 33.3) has a — (i) centrum, the modified notochord (ii) two laterally projecting transverse process (iii) a neural canal through which passes the spinal cord (iv) a mid dorsal neural spine formed by the union of neural arch. Depending upon their location in the body, secondary modifications are seen in the length of transverse process and the length of neural spine. The two neighbouring vertebrae articulate with each other through their anterior and posterior zygapophyses. Intervertebral discs are present between the centra of two neighbouring vertebrae.

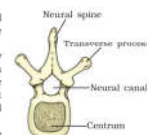


Fig. 33.3 A typical vertebra



Fig. 33.2 Vertebral column

Note: The vertebral column forms the central axis of the body and keeps it erect. It encloses and protects the spinal cord and provides surface for the attachment of skull, ribs, pectoral and pelvic girdles, as well as several muscles in the neck, thorax, abdomen and waist.

(c) Rib Cage and Sternum

- Sternum forms the floor of branchial basket. It bears 7 (seven) notches for articulation with ribs. It has hexagonal disc at the top called manubrium. Lower end has a reduced bone called xiphoid process (Fig. 33.4).

- (ii) Ribs can be put under two classes: the thoracic ribs, and the sternal ribs. The thoracic ribs articulate with the thoracic vertebrae, and the sternal ribs do so with the sternum. Some (7) of the thoracic ribs are attached to the sternal ribs with the help of ligaments, enabling the increase and decrease in volume of the thoracic chamber during respiration.
- (iii) There are 12 (twelve) pairs of thoracic ribs. Each rib is a thin flat bone and is carried ventrally from the vertebral column. It has a head articulating with the centrum, and tubercle articulating with transverse process of vertebrae (Fig. 33.4).
- (iv) 7 (seven) pairs of thoracic ribs are attached to the sternal ribs.
- (v) Last 5 (five) pairs of thoracic ribs do not articulate with sternal ribs, and are called false ribs. Among these, the last 2 (two) pairs of false ribs are free and are called floating ribs.

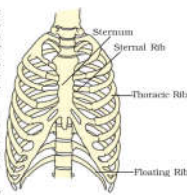


Fig. 33.4 Rib cage and sternum

Note: Rib-cage and sternum covers and protects the vital organs such as heart and lungs. The ribs are also helpful in breathing.

(d) Pectoral Girdle

- (i) It consists of a clavicle and a scapula (Fig. 33.5).
- (ii) Scapula is a large triangular flat bone with a slightly elevated ridge called spine. The spine projects as a flat, expanded process called the acromion.
- (iii) The clavicle is a long slender bone with two curvatures. The clavicle articulates with the acromion.
- (iv) Below the acromion is a depression called the glenoid cavity, for articulation of the head of the humerus to form the shoulder joint.

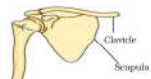


Fig. 33.5 Pectoral Girdle

Note: Pectoral girdle is formed of two halves. Each half consists of a scapula and a clavicle. The clavicle is commonly called collar bone. The third element of vertebrate pectoral girdle, the coracoid is highly reduced in man, and is present only by a small projection over the glenoid cavity.

(e) Pelvic Girdle

- (i) It consists of two halves.
- (ii) Each half is formed by the fusion of three bones – ilium, ischium and pubis (Fig. 33.6).
- (iii) At the point of fusion of the above bones is a cavity called acetabulum to which the thigh bone articulates.

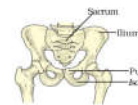


Fig. 33.6 Pelvic Girdle

- (iv) The two halves of the pelvic girdle meet ventrally to form the pubic symphysis.

Note: Pelvic girdle is commonly called hip bone. The ilium articulates anteriorly with the flat transverse process of sacral vertebrae.

(f) Bones of the Hand or Fore Limb

- (i) It is made up of bones consisting of humerus, radius and ulna, carpals, metacarpals and phalanges (Fig. 33.7).
- (ii) Humerus is a straight bone with a long shaft, and forms the upper arm. The head of the humerus fits into the glenoid cavity of the pectoral girdle. It has a crest at its proximal end in the form of deltoid ridge for the attachment of arm muscles. The distal end has a foramen and a trochlear process, which forms elbow joint with radius and ulna.
- (iii) Radius-ulna consists of 2 (two) separate bones of the forearm namely radius and ulna. Ulna is more developed and has olecranon process at its proximal end, which forms elbow joint with humerus.
- (iv) Carpals consist of 8 (eight) small bones arranged in two rows. It forms the wrist (Fig. 33.8).
- (v) Metacarpals are made up of 5 (five) long bones forming the palm of hand.
- (vi) Phalanges consist of 2 (two) in the thumb and 3 (three) bones in the remaining four fingers, thus totalling 14 (fourteen) bones.

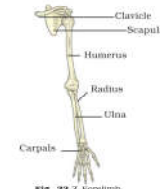


Fig. 33.7 Forelimb

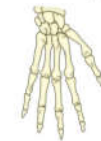

Fig. 33.8 Carpals, Metacarpals and Phalanges

(g) Bones of the Leg or Hind Limb

- (i) It is made up of femur, tibia and fibula, patella (knee cap) tarsals, metatarsals, phalanges (Fig. 33.9).
- (ii) The femur is the longest bone. The head of femur fits into the acetabulum of the pelvic girdle. The proximal end has trochanters for attachment of thigh muscles. The distal end has two condyles, which articulate with triangular shaped patella and proximal part of tibia to form knee on the ventral side.

Exercise 34

Aim: To study different types of joints in human skeleton.

Principle: Bones may be movable, slightly movable or immobile depending on the nature of joints. Joints are defined as regions/surfaces of contact between bone and cartilage.

Requirement: Specimen of human skeleton, charts and models of skeleton.

Procedure

- (i) Observe the different types of bones and joints present in a human skeleton.
- (ii) Draw labeled diagram of your observations.

Observation

(a) Gliding Joints

- (i) These are flat joints, which allow back and forth or side-to-side movement of all or a few joining elements. However, twisting is not possible.
- (ii) These joints are found between bones of tarsals and carpals (Fig. 34.1).

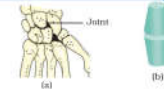


Fig. 34.1 Gliding Joints (a) hind limb bones showing the joint (b) Diagrammatic representation

(b) Pivot Joints

- (i) These joints allow rotational movement.
- (ii) These joints are found between the atlas and axis vertebrae of backbone. It is the odontoid process of the axis vertebra over which the atlas along with the skull rotate (Fig. 34.2).

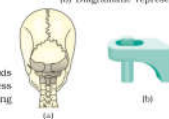

Fig. 34.2 Pivot Joints (a) Skull and vertebral column showing the joint (b) Diagrammatic representation

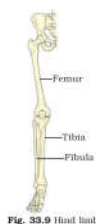

Fig. 33.9 Hind limb

- (iii) Tibia-fibula consists of two separate bones namely tibia and fibula and is present in the shank region of leg. Tibia is more developed than fibula. Its proximal end articulates with femur and patella and forms knee.
- (iv) There are 7 (seven) tarsal bones, which are arranged in two rows to form the ankle. The largest bone of these is calcaneus which form heel (Fig. 33.10).
- (v) Metatarsals consist of 5 (five) bones and form foot.
- (vi) Phalanges consist of 2 (two) bones in big toe and three bones in each of the remaining toes thus totaling 14 (fourteen) bones.

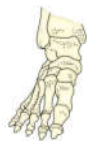

Fig. 33.10 Tarsals



UPDATED ZOOLOGY CLASS -XI



SN	Chapter Name	Added Portion	Deleted Portion
6	Locomotion and Movement	Dealt with Relevant Practical Syllabus	-
7	Neural Control and Coordination	-	Reflex Action & Reflex Arc, Sensory Reception
8	Chemical Coordination and Integration	-	-
9	Animal Kingdom (General Account & Non-Chordates)	-	-
10	Animal Kingdom (General Account & Chordates)	-	-

Source - <https://www.nmc.org.in/neet/neet-ug/>



UPDATED ZOOLOGY CLASS -XII



SN	Chapter Name	Added Portion	Deleted Portion
1	Reproduction in Organisms	-	Deleted
2	Human Reproduction	-	-
3	Reproductive Health	-	-
4	Evolution	-	-
5	Human Health & Diseases	Dengue , Chikungunya	-

Source - <https://www.nmc.org.in/neet/neet-ug/>



UPDATED ZOOLOGY CLASS -XII



SN	Chapter Name	Added Portion	Deleted Portion
6	Strategies for Enhancement in Food Production - Animal Husbandry	-	Major part Deleted except: Tissue Culture
7	Biotechnology - Principles and Processes	-	-
8	Biotechnology and its Applications	-	Tissue Culture

Source - <https://www.nmc.org.in/neet/neet-ug/>